

# Novel non-destructive 3D ex-vivo ocular vasculature evaluation: $\mu$ Angiofil in microCT

Petr Soukup<sup>1,2</sup>, David Haberthür<sup>3</sup>, Simon A. Pot<sup>1</sup>, Peter M. Maloca<sup>4,5</sup>, Bernd Altmann<sup>2</sup>, and Ruslan Hlushchuk<sup>3</sup>

<sup>1</sup>Section of Ophthalmology, Equine Department, Vetsuisse Faculty, University of Zurich, Switzerland; <sup>2</sup>Roche Innovation Center Basel, Basel, Switzerland; <sup>3</sup>Institute of Anatomy, University of Bern, Switzerland; <sup>4</sup>OCTlab Research Laboratory, Department of Ophthalmology, University of Basel, Switzerland; <sup>5</sup>Moorfields Eye Hospital, London, United Kingdom

## 1. Introduction

Traditionally, scanning electron microscopy of vascular corrosion casts, which is destructive to the ocular tissues, has been used for high-resolution 3D rendering of the ocular vasculature.<sup>1,2</sup> A novel imaging technique enables these investigations in a non-destructive manner.<sup>3</sup> **Purpose:** To evaluate a novel ex vivo polymerizing vascular contrast agent and micro computed tomography (microCT) technology for visualization of the ocular vasculature in laboratory animals.

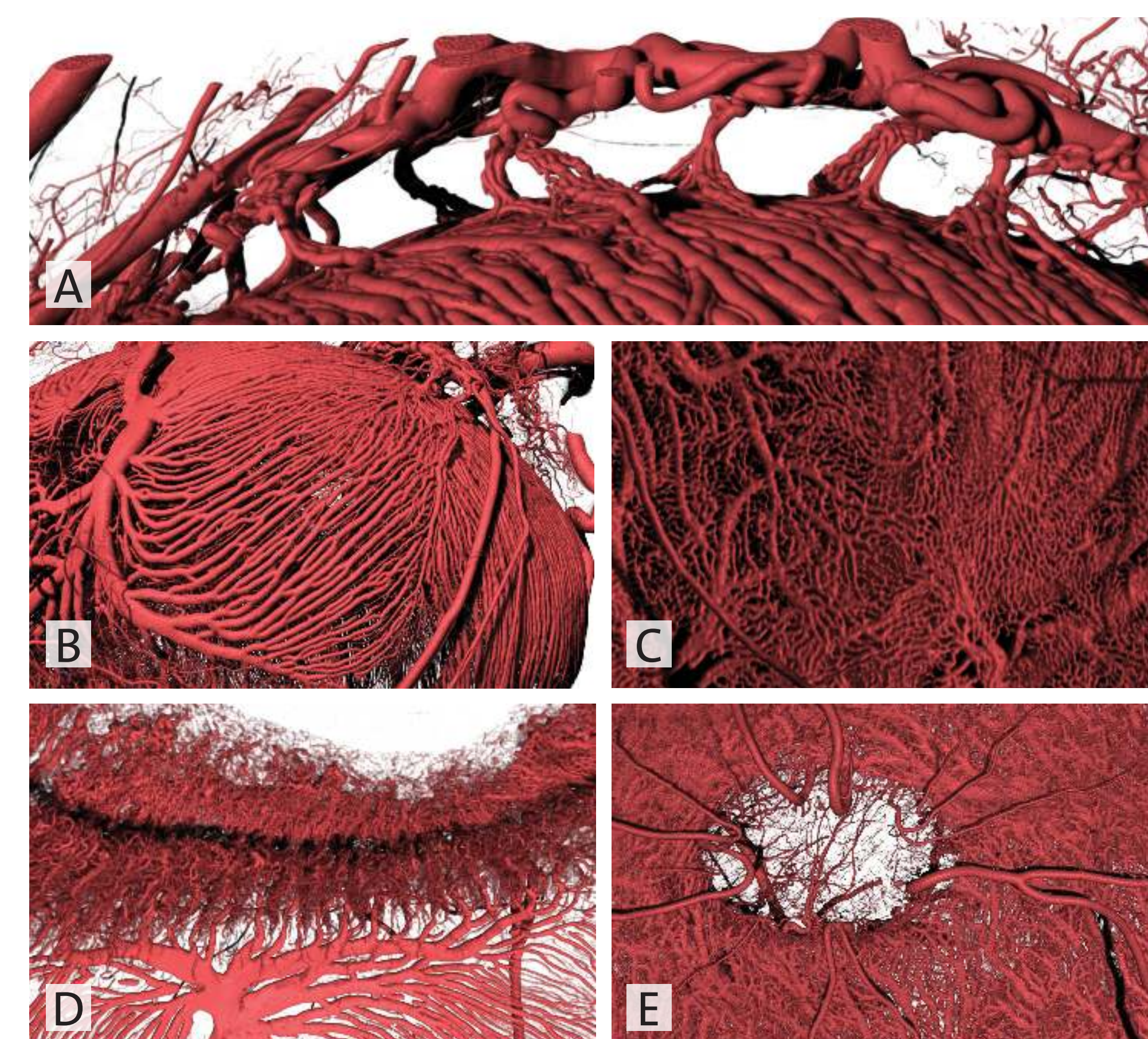
## 2. Methods

Animals were heparinized and euthanized in terminal anesthesia, then sequentially perfused with saline and the novel contrast agent  $\mu$ Angiofil (Fumedica, Switzerland). Mice and rats were perfused via heart, rabbits via aorta ascendens and minipigs via carotid artery. Globes were enucleated and fixed in 10% formalin for 48 hours, then scanned with various resolutions using microCT (SkyScan 1272, Bruker, Belgium). 3D reconstruction and qualitative sample evaluation followed in CTvox (Bruker, Belgium). Ten eyes (3 minipig, 2 rabbit, 3 rat, 2 mouse) from nine animals were imaged.

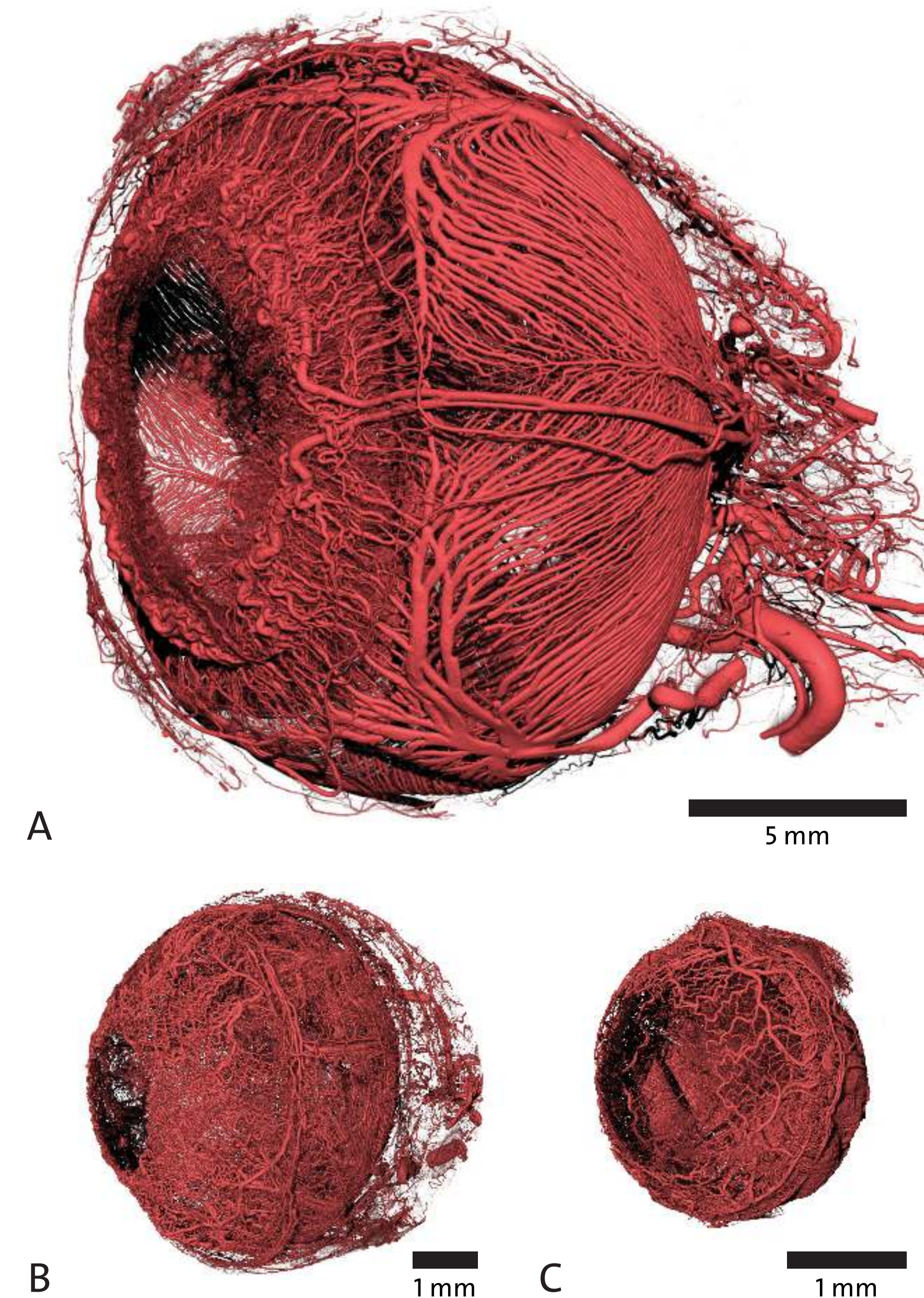
## 3. Results

Different resolutions were required to optimally image complete globes, large ocular vessels and capillary beds of choroid, retina and iris (Table 1). Higher resolution increased detail and data size. The best resolution achieved was 0.8  $\mu$ m/pixel. Several fill artifacts which did not interfere with sample evaluation were noted in each specimen.

Structure imaged	Resolution required
Minipig and rabbit globe	6.6 $\mu$ m/pixel
Rat globe	1.8 $\mu$ m/pixel
Mouse globe	0.8 $\mu$ m/pixel
Large ocular vessels	6.6 $\mu$ m/pixel
Capillary beds detection limit	2.4 $\mu$ m/pixel
Capillary beds detailed structure	0.8 $\mu$ m/pixel



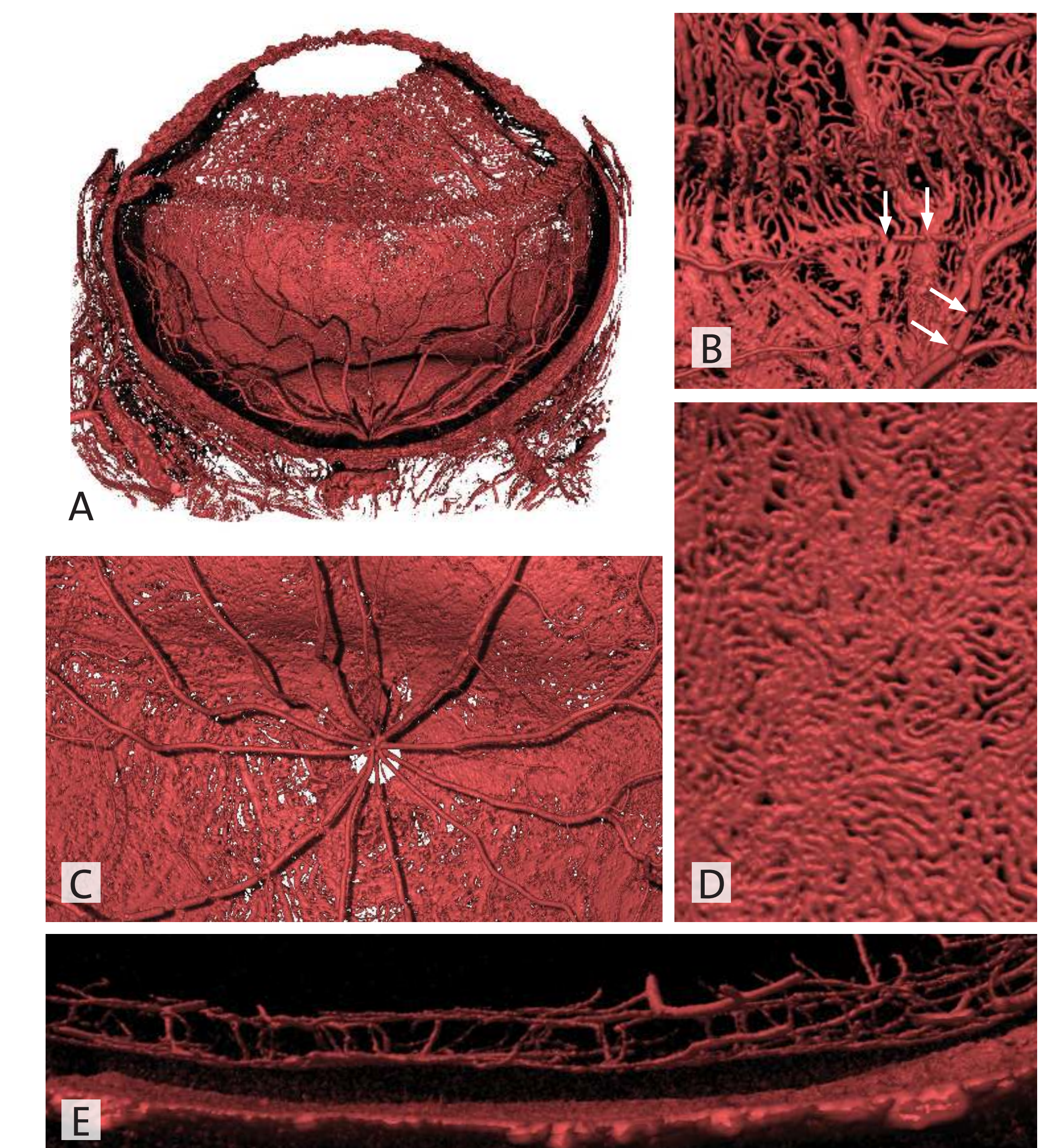
**Figure 2:** Minipig eye. A: focus on penetrating branches of short posterior ciliary arteries, 6.6  $\mu$ m/px. B: choroidal vasculature with arterial inflow on the right and venous outflow on the left, ab externo, 6.6  $\mu$ m/px. C: choriocapillaris meshwork detail, ab interno, 2.4  $\mu$ m/px. D: iris, ciliary body and vortex vein, ab interno, 6.6  $\mu$ m/px. E: optic nerve head with arteries – veins not filled, ab interno, 2.4  $\mu$ m/px.



**Figure 3:** Whole globes. A: minipig, 6.6  $\mu$ m/px. B: rat, 1.8  $\mu$ m/px. C: mouse, 0.8  $\mu$ m/px.

## 4. Conclusion

$\mu$ Angiofil microCT imaging yielded high quality data useful for quantitative and qualitative assessment of the ocular vasculature. Moreover, this technique is not destructive to the scanned samples, which can be further processed for correlative histology.



**Figure 4:** Rat eye. A: view into distant half of the eye, 1.8  $\mu$ m/px. B: ciliary body detail with white arrows marking filling artifacts (non-continuous vessels) 1.8  $\mu$ m/px. C: optic nerve head and vasculature, 1.8  $\mu$ m/px. D: choriocapillaris meshwork detail, 1.0  $\mu$ m/px. E: cross sectional view of superficial and deep retinal capillary plexus at the top, interspersed avascular space and choroidal vasculature at the bottom, 1.0  $\mu$ m/px.



**Figure 5:** Toluidine blue stained plastic section of rat retina. All vascular structures are filled with homogenous light blue colored  $\mu$ Angiofil (black arrows). Note the superficial and deep retinal and choroidal vessels also outlined in Figure 4E.

## References

- Simoens P et al. Morphologic and clinical study of the retinal circulation in the miniature pig. A: Morphology of the retinal microvasculature. *Exp Eye Res* 1992;54:965-973.
- Ninomiya H et al. Microvasculature of the rat eye: scanning electron microscopy of vascular corrosion casts. *Vet Ophthalmol* 2001;4:55-59.
- Hlushchuk R et al. Cutting-edge microangio-CT: new dimensions in vascular imaging and kidney morphometry. *American Journal of Physiology-Renal Physiology* 2018;314:F493-F499.



**Figure 1:** Enucleated eye with blue  $\mu$ Angiofil visible in the long posterior ciliary artery and conjunctival microvasculature.